EPITHELIAL PATHOLOGY

LAB:18-19

DR.NOOR

Squamous Papilloma. A pedunculated lingual mass with numerous long, pointed, and white surface projections. Note the smaller projections around the base of the lesion.

Squamous Papilloma. Low-power view showing a pedunculated squamous epithelial proliferation. There are multiple papillary projections with fibrovascular connective tissue cores.

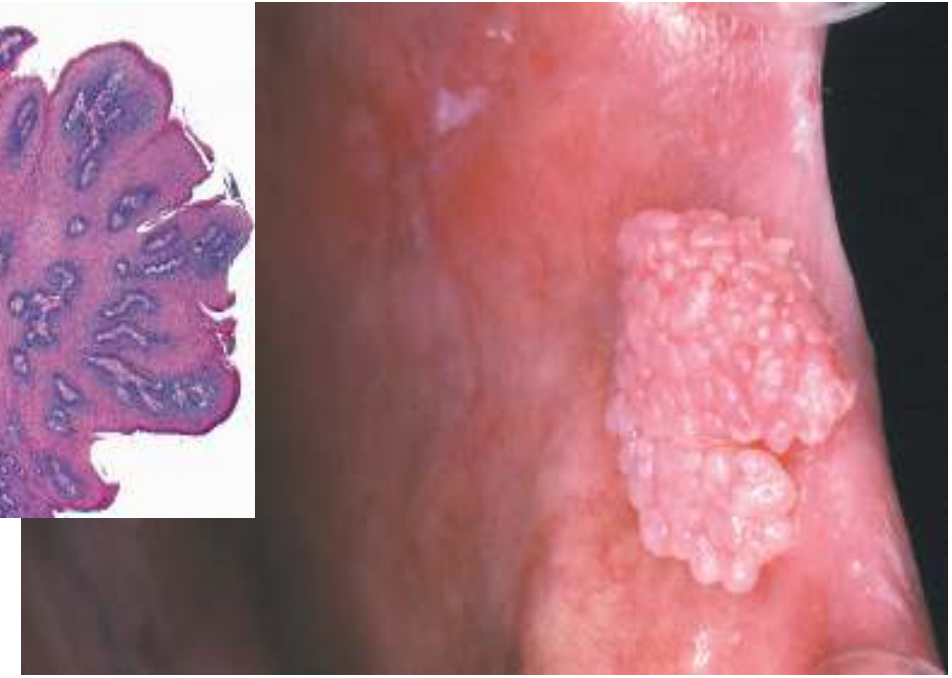

Squamous Papilloma. A pedunculated mass of the buccal commissure, exhibiting short or blunted surf projections and minimal white coloration.

REACTIVE LESIONS:

Focal (Frictional) Hyperkeratosis

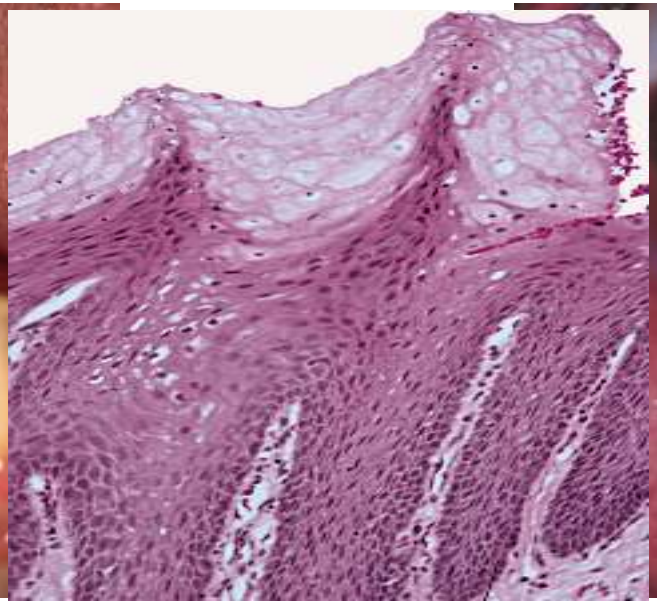

Tobacco Pouch Keratosis, was located in the area of chronic chewing tobacco placement leathery, white, fissured plaque of the right mandibular vestibule, which Severe. A somewhat

acanthosis, hyperparakeratosis, and “chevron” formation. Epithelium exhibiting

Tobacco Pouch Keratosis, and not associated with the keratosis. chronic snuff placement. The gingival melanosis is racial pigmentation gray-white lesion of the lower labial mucosa located in the area of Mild. A soft, fissured,

Nicotine Stomatitis. Close-up of the inflamed ductal openings of involved salivary glands of the hard palate. Note the white keratotic ring at the lip of many of the inflamed ducts.

Nicotine Stomatitis. This extensive leathery, white change of the hard palate in a pipe smoker is sprinkled throughout with numerous red papules, which represent inflamed salivary duct openings. The gingival mucosa also is keratotic

Hairy Leukoplakia

- is related to the presence of epstein-barr virus **(EBV)** and is found almost exclusively in human immunodeficiency virus (HIV)–infected individuals.
- Vast majority of cases have been located along the **lateral margins** of the tongue, with occasional extension onto the dorsal surface

- **Histopathology:**
- The characteristic microscopic feature of hairy leukoplakia is found in the nuclei of upper level keratinocytes. Viral inclusions or peripheral displacement of chromatin with a resultant smudgy nucleus is evident.
- Beneath the surface, within the spinous cell layer, cells show **ballooning degeneration** and perinuclear clearing.
- In situ hybridization studies have demonstrated the presence of EBV within cells, showin homogenization

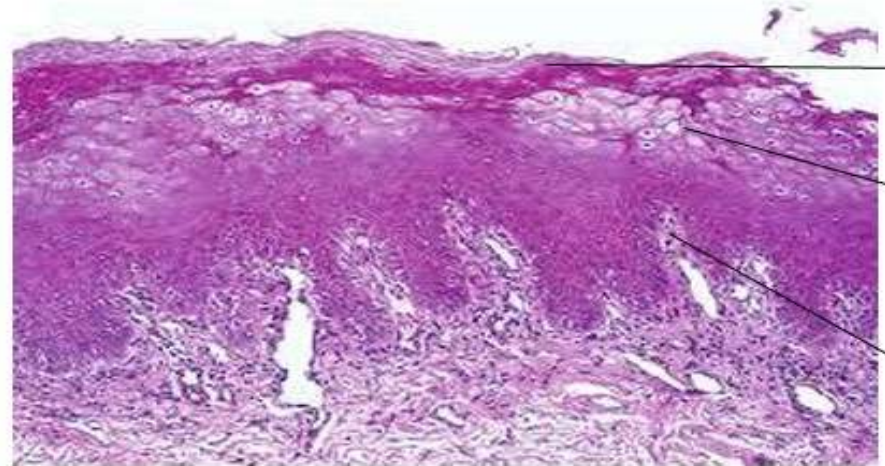

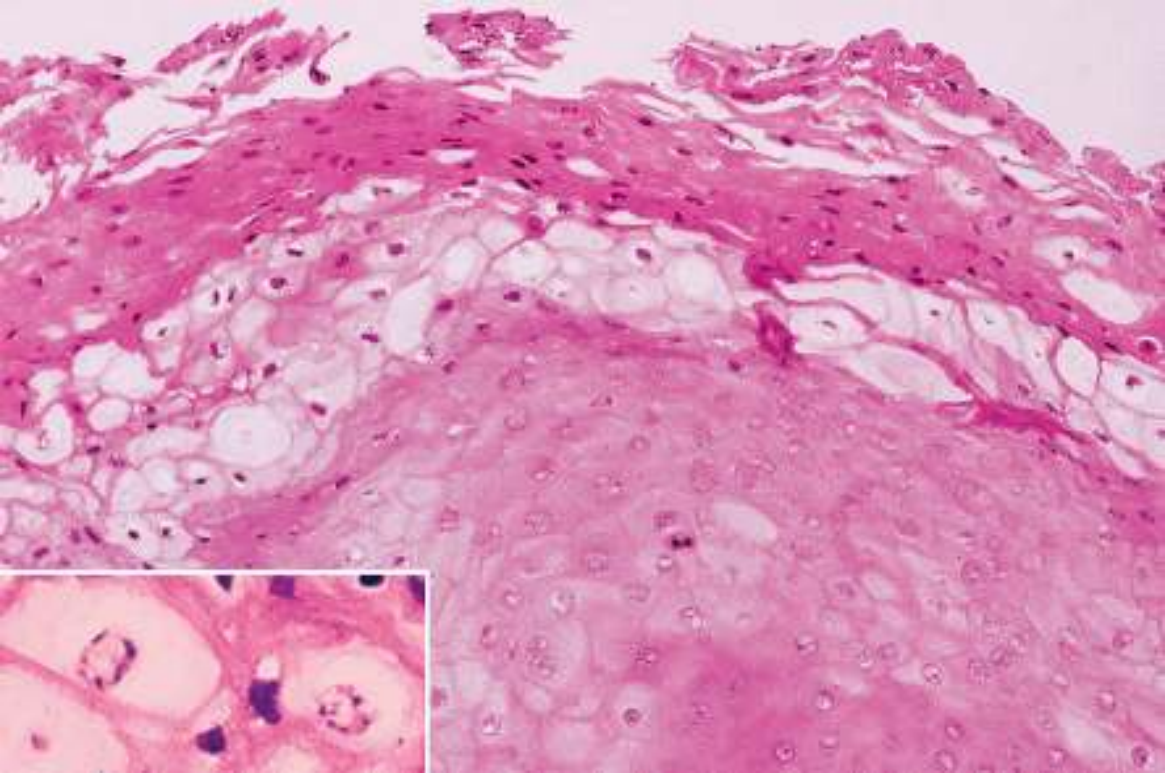

HIV-associated Oral Hairy Leukoplakia (OHL). Oral epithelium exhibiting hyperparakeratosis and layer of "balloon cells" in the upper spinous layer. Inset reveals high -power magnification of epithelial cells that demonstrate **nuclear beading.**

HIV-associated Oral Hairy Leukoplakia

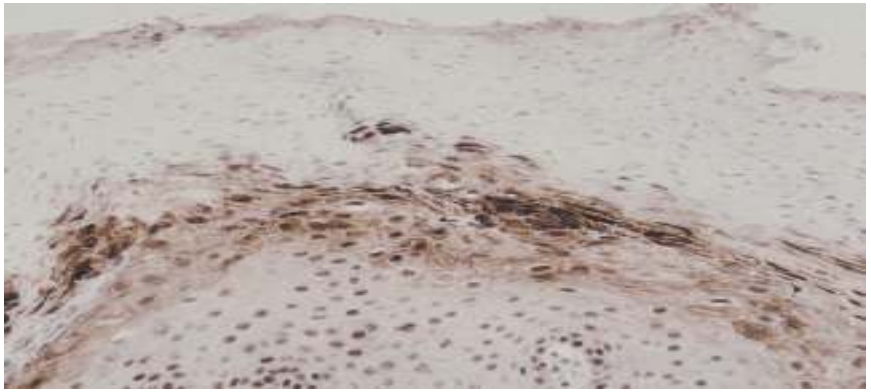

HIV-associated Oral Hairy Leukoplakia (OHL). Immunoperoxidase evaluation for Epstein-Barr virus (EBV) revealing positive reaction within numerous epithelial cells.

hairy leukoplakia & AIDS

- 10% ⟷ diagnosed have at the time of diagnosis,
- 20% ⟷ develop this disease in the following year.
- 50% within 1.5 years.
- 80% within 2.5 years.

Squamous Cell Carcinoma Arising in Actinic Cheilosis.
Patient with actinic cheilosis of the lower lip, who developed a small, chronic ulceration. Biopsy revealed early invasive squamous cell carcinoma.

Actinic Cheilosis. Crusted and ulcerated lesions of the lower lip vermilion.

Idiopathic Leukoplakia

- **Leukoplakia is a clinical term indicating a white patch or plaque of oral mucosa that cannot be rubbed off and cannot be characterized clinically as any other disease.**
- Approximately **5%** of leukoplakias are **malignant** at the time of first biopsy, and approximately **5%** of the remainder undergo subsequent malignant transformation.
- From 10% to 15% of dysplasias that present as clinical leukoplakia will develop into squamous cell carcinoma.
- floor of the mouth,

- A Red zones may also be seen in some leukoplakias, prompting use of the term speckled leukoplakia **(erythroleukoplakia).**
- ⬆ malignant transformation

Proliferative verrucous leukoplakia (PVL)

- This type of leukoplakia begins as simple keratosis and eventually becomes verrucous in nature.
- Histologic changes range from hyperkeratosis, dysplasia, and carcinoma in situ to invasive squamous cell carcinoma.

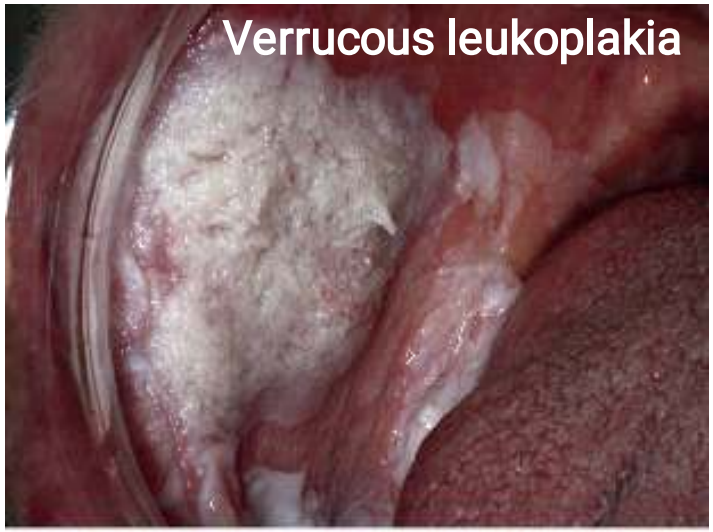

Microscopic characteristics of dysplasia:

- The term dysplasia indicates abnormal epithelium and disordered growth, whereas **atypia** refers to abnormal nuclear features , Specific microscopic characteristics of dysplasia include:
- 1-increased and abnormal mitoses.
- 2-basal cell hyperplasia
- 3-drop-shaped rete pegs
- 4-distributed polarity of the basal cell layers
- 5-alteration (invariably an increase) is seen in the nuclear/cytoplasmic ratio
- 6-nuclear hyperchromatism.
- 7-prominent and enlarged nucleoli
- 8-irregular epithelial stratification
- 9-nuclear and cellular pleomorphism
- 10-abnormal keratinization
- 11-loss or reduction of intercellular adhesion

- It is generally accepted that the more severe the epithelial changes, the more likely a lesion is to evolve into cancer.
- Increasing degrees of dysplasia are designated as **mild, moderate, and severe** and are subjectively determined microscopically.
- **Mild epithelial dysplasia** refers to alterations limited principally to the basal and parabasal layers, **Moderate epithelial dysplasia** demonstrate involvement from the basal layer to the midportion of the spinous layer .
- **Severe epithelial dysplasia** demonstrates alterations from the basal layer to a level above the midpoint of the epithelium.

- . When the entire thickness of epithelium is involved with these changes in a so-called top-to-bottom pattern, the term **carcinoma in situ** may be used.

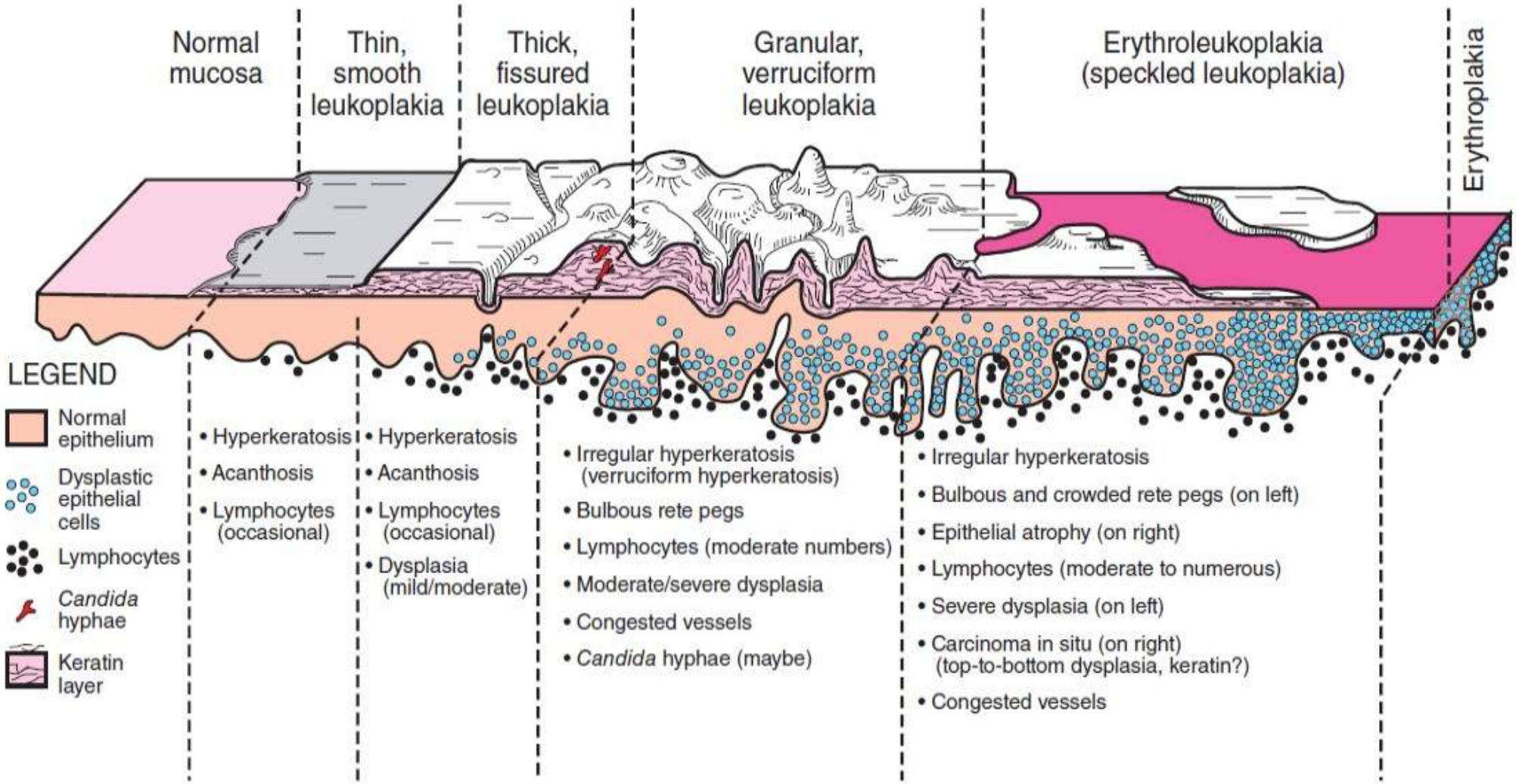
Normal mucosa
Thin, smooth leukoplakia
Thick, fissured leukoplakia
Granular, verruciform leukoplakia
Erythroleukoplakia (speckled leukoplakia)
Erythroplakia
LEGEND
Normal epithelium
Dysplastic epithelial cells
Lymphocytes
Candida hyphae
Keratin layer
• Hyperkeratosis
• Acanthosis
• Lymphocytes (occasional)
• Hyperkeratosis
• Acanthosis
• Lymphocytes (occasional)
• Dysplasia (mild/moderate)
• Irregular hyperkeratosis (verruciform hyperkeratosis)
• Bulbous rete pegs
• Lymphocytes (moderate numbers)
• Moderate/severe dysplasia
• Congested vessels
• Candida hyphae (maybe)
• Irregular hyperkeratosis
• Bulbous and crowded rete pegs (on left)
• Epithelial atrophy (on right)
• Lymphocytes (moderate to numerous)
• Severe dysplasia (on left)
• Carcinoma in situ (on right) (top-to-bottom dysplasia, keratin?)
• Congested vessels

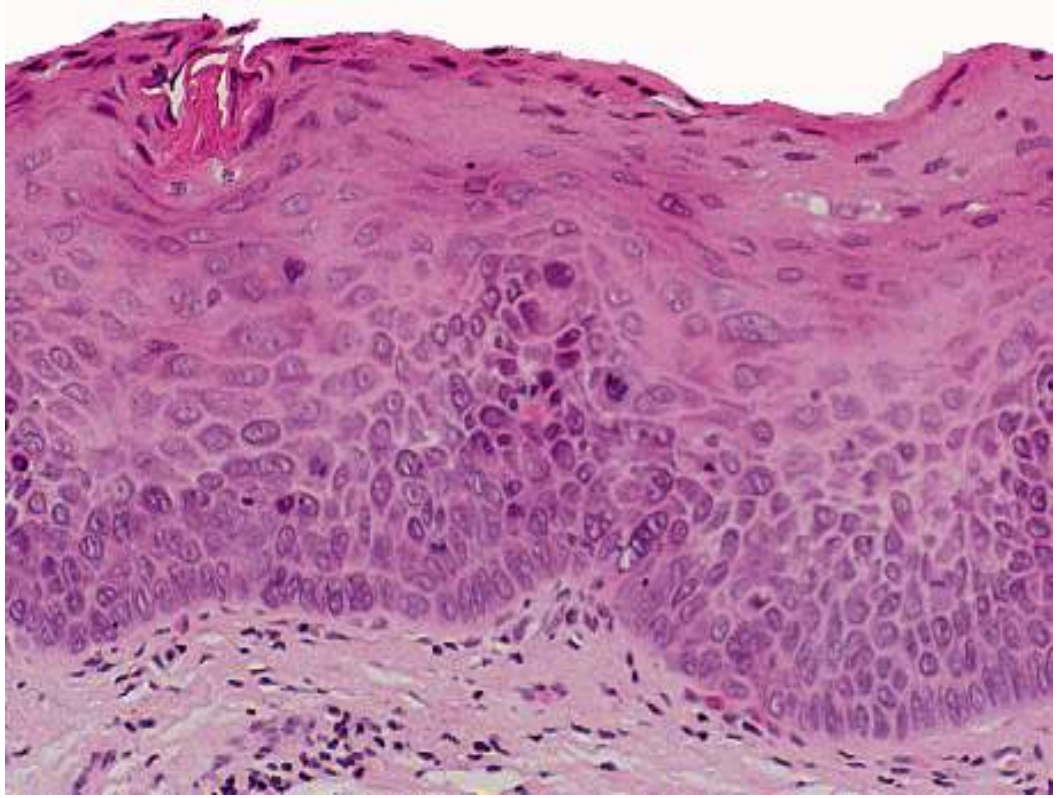

Moderate Epithelial Dysplasia. Dysplastic changes extend to the **midpoint** of the epithelium and are characterized by nuclear hyperchromatism, pleomorphism, and cellular crowding.

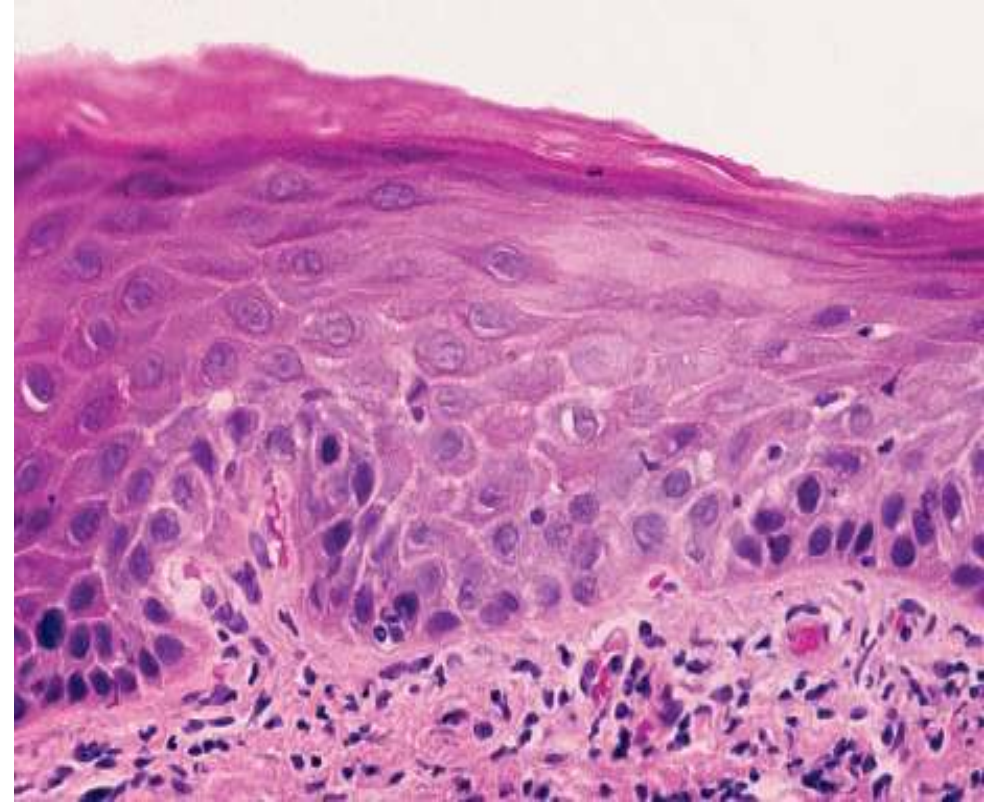

Mild Epithelial Dysplasia. Hyperchromatic and slightly pleomorphic nuclei are noted in the basal and parabasal cell layers of this stratified squamous epithelium

Homogeneous or Thick Leukoplakia.
Extensive buccal mucosal lesion with uneven whiteness and fissures.
Moderate epithelial dysplasia was noted on histopathologic evaluation, and squamous cell carcinoma later developed in this area.

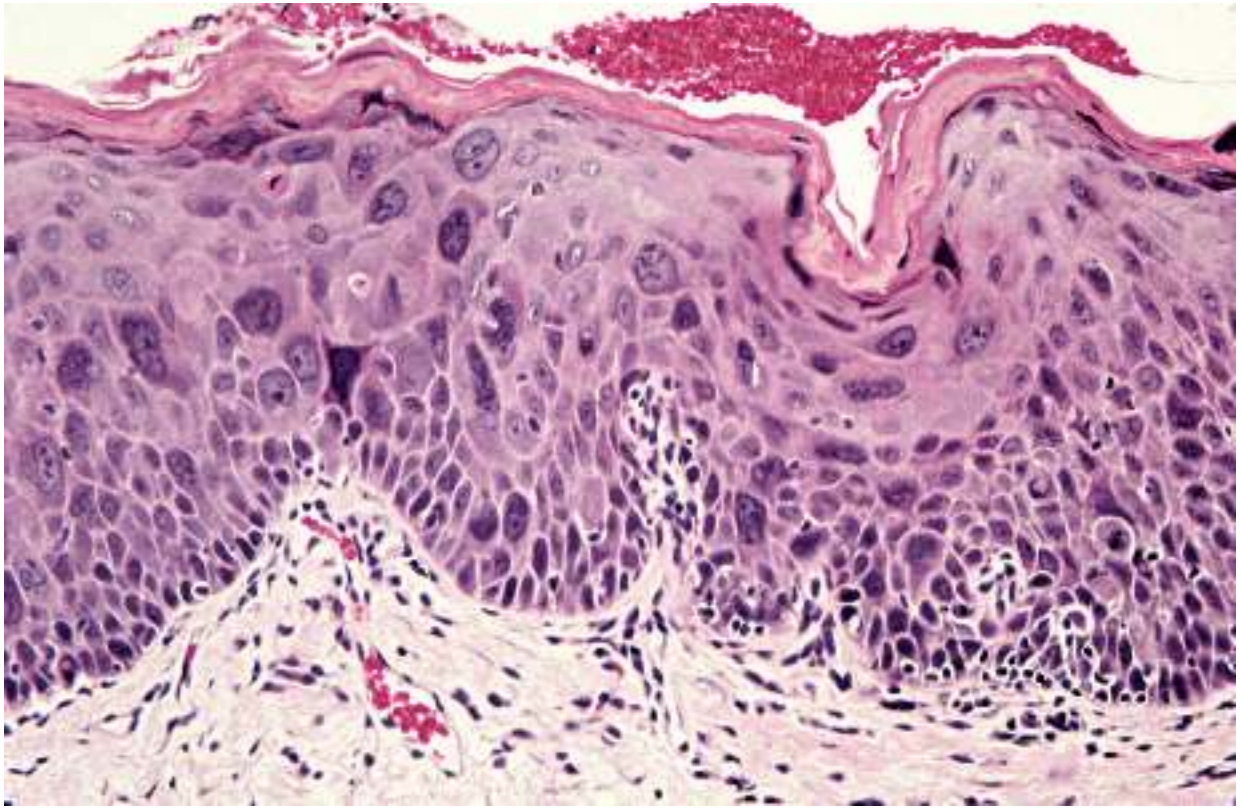

Severe Epithelial Dysplasia. Epithelium exhibiting marked pleomorphism, hyperchromatism, and scattered mitotic figures. Atypical cells involve most of the epithelial thickness.

Erythema Migrans. Striking involvement of the dorsal and lateral surfaces of the tongue.

Erythema Migrans.. The lateral distribution of the lesion is shown.

Histopathology.

- Filiform papillae are atrophic, and the margins of the lesion demonstrate hyperkeratosis and acanthosis. Closer to the central portion of the lesion, corresponding to the circinate erythematous areas, loss of keratin is noted, along with intraepithelial neutrophils and lymphocytes.
- Leukocytes are often noted within a microabscess near the surface. An inf lammatory cell inf ltrate within the underlying lamina propria, consisting chief ly of neutrophils, lymphocytes, and plasma cells. **Treatment and Prognosis** Because of the self-limiting and usually asymptomatic nature of this condition, treatment is not required
- sodium bicarbonate in water mouth wash . Topical steroids, especially those containing an antifungal agent, may be helpful

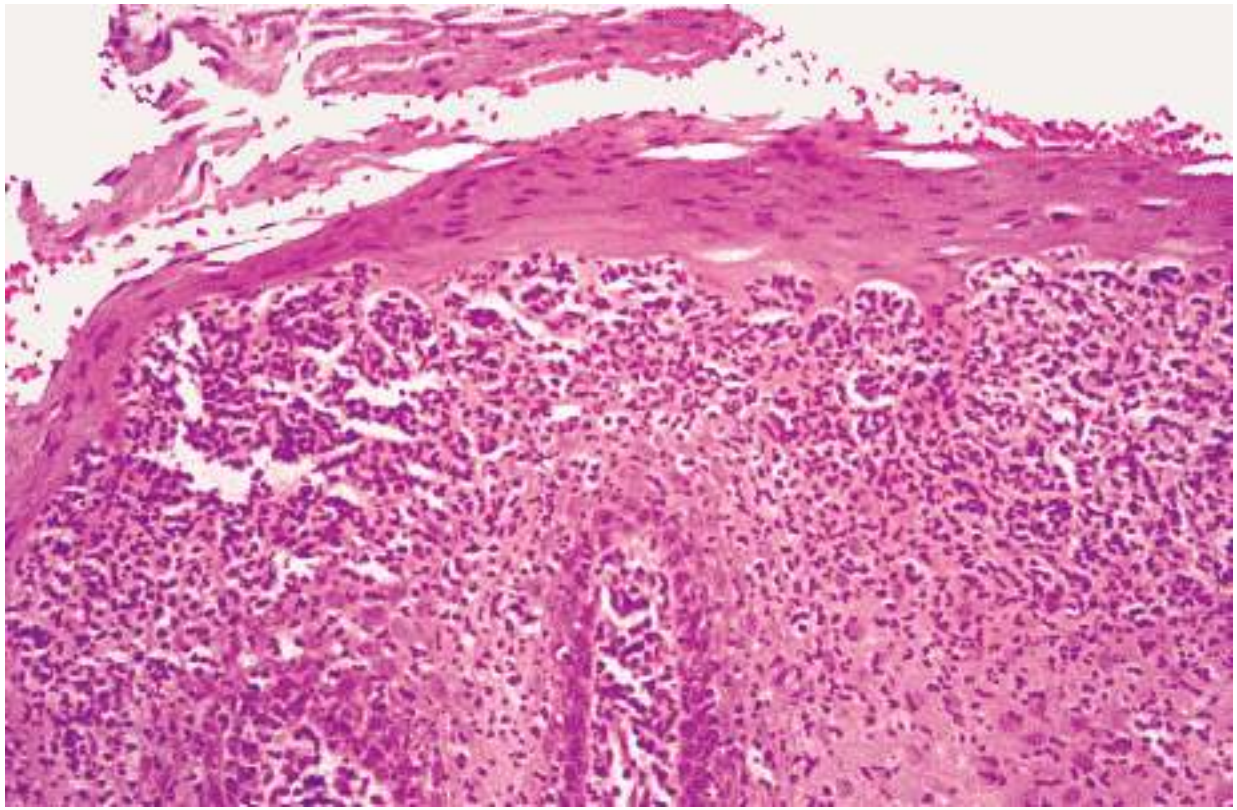

Erythema Migrans. This medium-power photomicrograph shows collections of neutrophils in the superficial spinous layer
of the epithelium.

Lichen Planus

- **(Wickham's striae)** lacelike network of white lines.
- Essentially there are two forms of oral lesions:
- **(1) reticular and (2) erosive.**

Lichen Planus. The interlacing white lines and papules are typical of reticular lichen planus involving the buccal mucosa, the most common site of oral involvement.

Lichen Planus. Closer view **of a skin lesion** of lichen planus. Careful examination shows a network of fine white lines **(Wickham striae)** on the surface of the papules.

Lichen Planus. **A,** The dorsal surface of the tongue shows extensive ulceration caused by **erosive** lichen planus. Note the fine white streaks at the periphery of the ulcerations.
B, Same patient after **systemic corticosteroid therapy**. Much of the mucosa has reepithelialized, with only focal ulcerations remaining.

Lichen Planus. Ulceration of the buccal mucosa shows
peripheral radiating keratotic striae, characteristic of **oral erosive lichen planus.**

Lichen Planus. Erosive lichen planus often appears as a **desquamative gingivitis**, producing gingival erythema andtenderness.

- **The histopathologic features** of lichen planus are characteristic but may not be specific because other conditions such as lichenoid drug reaction, lichenoid amalgam reaction, lupus erythematosus are similar.
- The reteridges may be absent or hyperplastic, but they classically have a **pointed or "saw toothed" shape.**
- Destruction of the basal cell layer of the epithelium **(hydropic degeneration)** is also evident. This is accompanied by an intense, band like infiltrate of predominantly t-lymphocytes immediately subjacent to the epithelium.
- No significant degree of epithelial atypia is expected in oral lichen planus although lesions having a **superimposed candidal infection** may appear worrisome. These should be reevaluated histopathologically after the candidal infection is treated.

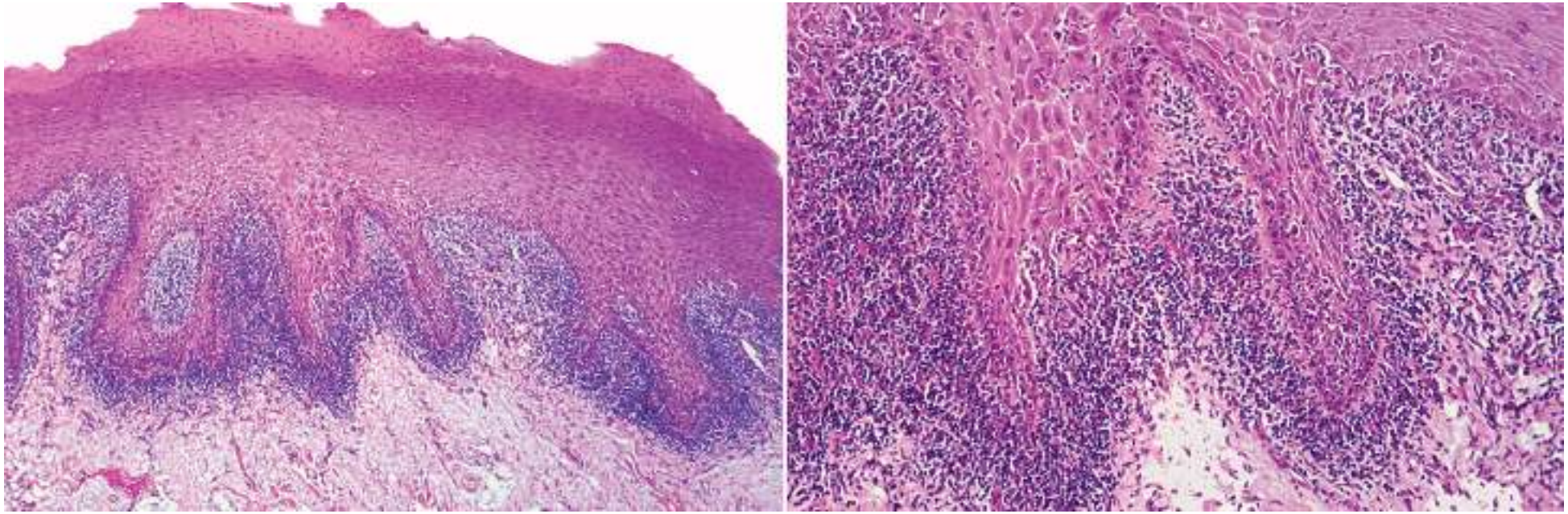

Lichen Planus. **A,** This low-power photomicrograph of an oral lesion shows hyperkeratosis, saw-toothed rete ridges, and a bandlike infiltrate of lymphocytes immediately subjacent to the epithelium.
B, Higher-power view showing migration of lymphocytes into the lower epithelium with interface degeneration of the basal cell layer

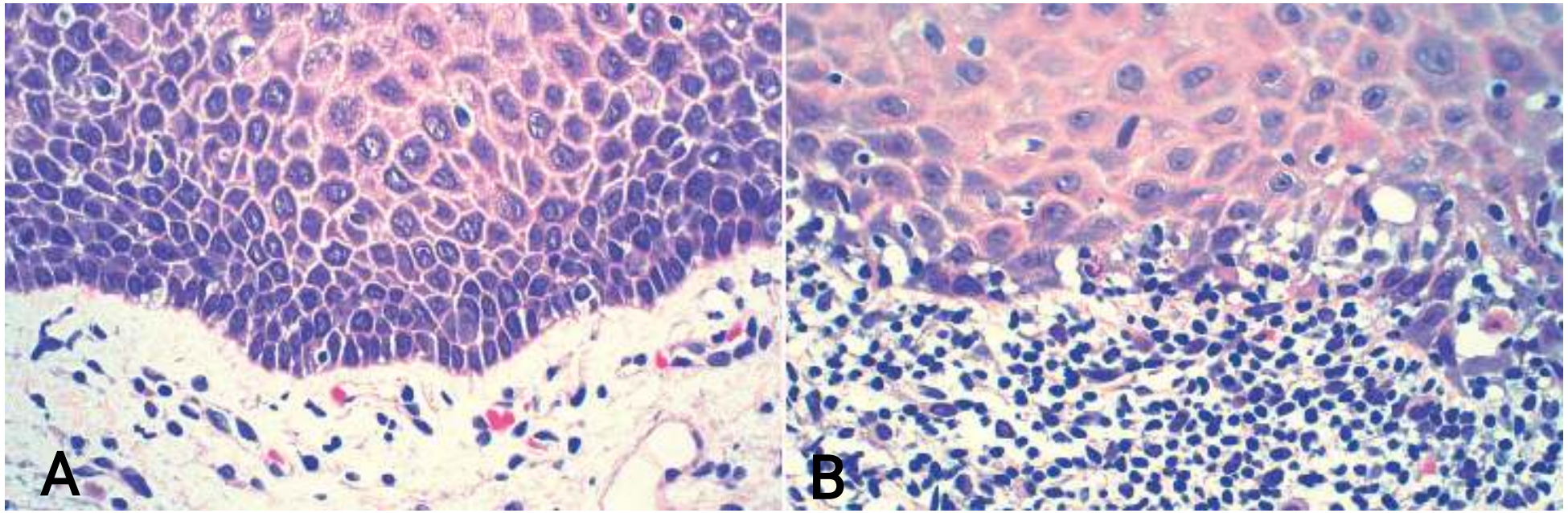

Lichen Planus. A, High-power photomicrograph of normal epithelium showing an intact basal cell layer and no inflammation.
B, High-power photomicrograph of lichen planus showing degeneration of the basal epithelial layer and an intense lymphocytic infiltrate in the superficial lamina propria.

Epithelial pathology null
PART-2

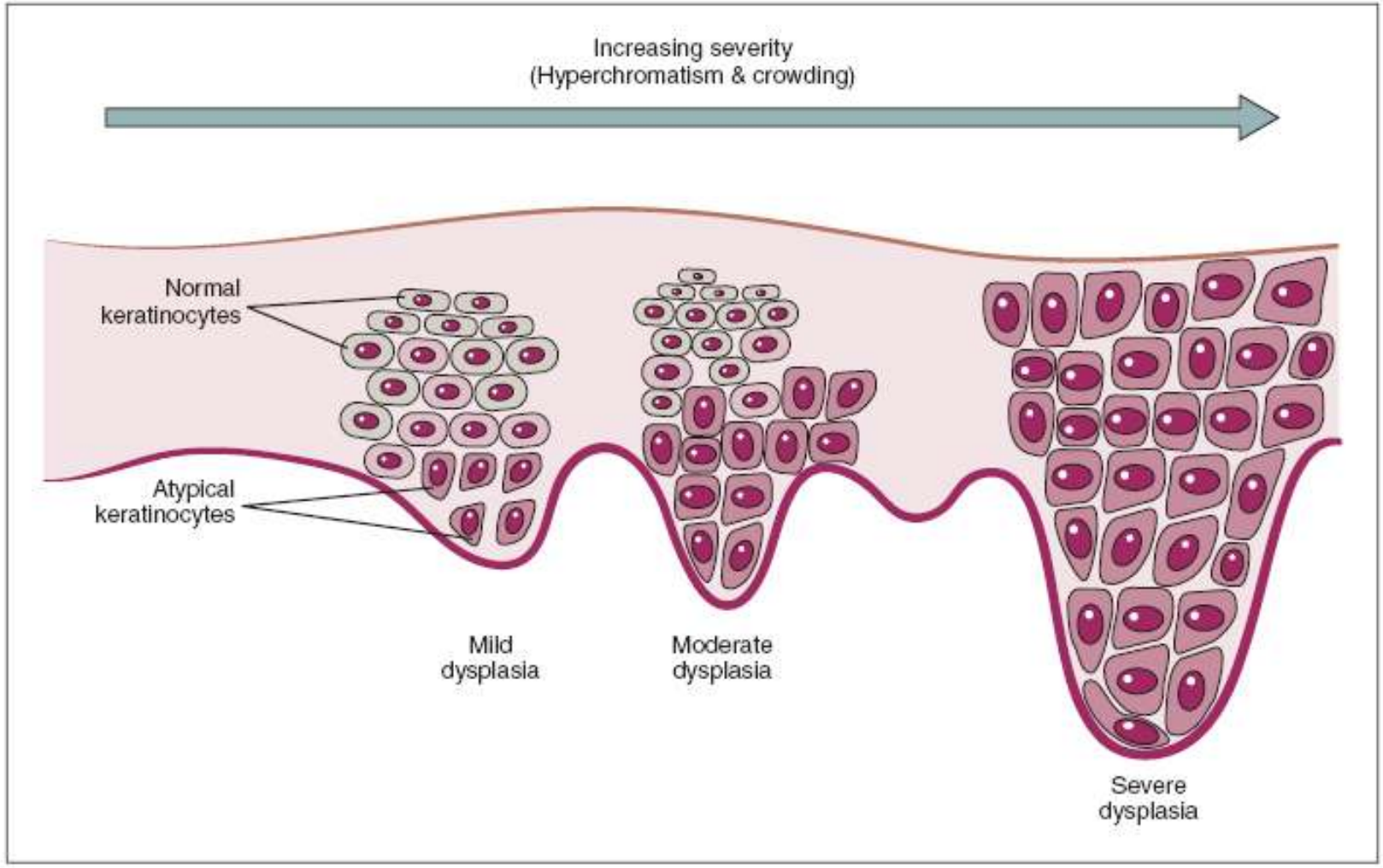

FIGURE 3-25 Progression of dysplasia.

Erythroplakia: Similar to leukoplakia, erythroplakia is def ined as a red patch or plaque that cannot be clinically or pathologically diagnosed as any other co

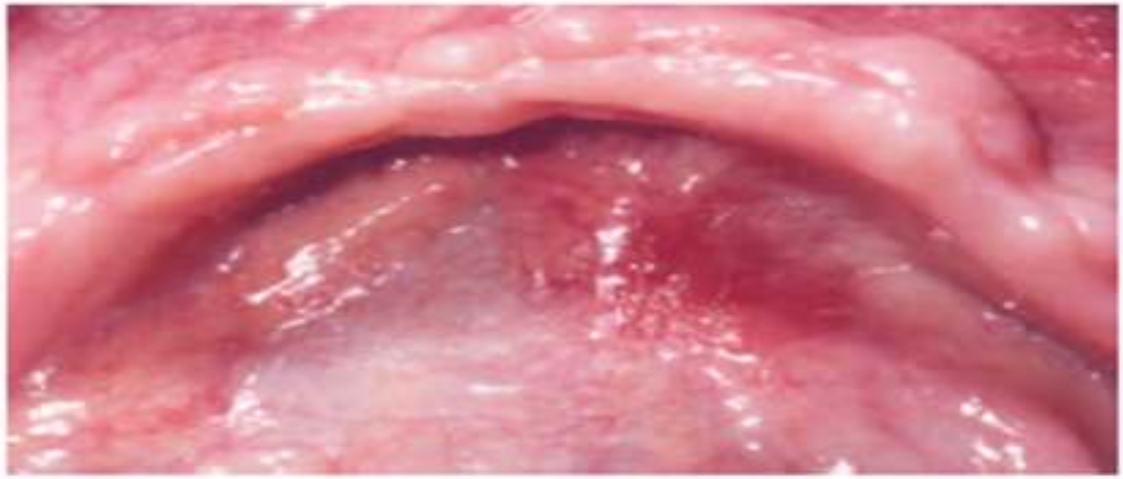

Fig. 10-76 Erythroplakia. An erythematous macular lesion is seen on the right floor of the mouth with no associated leukoplakia. Biopsy showed early invasive squamous cell carcinoma.

Squamous cell carcinoma (SCC)

Epidemiology Squamous cell carcinoma accounts for 90 percent or more of all oral malignant neoplasms.

In both the United Kingdom and the USA oral cancer accounts for less than 4 %of all cancers, but in India and South east Asia it accounts for up to **40** % of all malignant tumors.

It represents the eleventh most common cancer in males and the sixteenth most common in females.

Around 27,000 new cases of oral cancer are diagnosed annually, and approximately 5,500 individuals die of this disease each year.

Under normal circumstances cellular proliferation is controlled by the balance between these growth-promoting and growth-inhibiting genes.

During carcinogenesis a proto-oncogene may undergo mutation and become an activated oncogene, resulting in enhanced activity, and/or tumor-suppressor genes may be mutated or their products inactivated The result in both cases leads to deregulation of cell proliferation and tumor formation.

Oncogenes

Oncogenes encode For a range of growth-promoting proteins such as growth factor receptors, signal-transmitting proteins, and stimulatory cell-cycle regulating proteins.

In contrast, **tumor-suppressor genes** encode for growth-inhibitory proteins, such as p53 which plays a vital role in inhibiting the cell cycle and, if necessary, arresting the cycle and switching cells into apoptosis.

The most important oncogenes and tumor-suppressor genes to influence pathways controlling the first stages of the cell cycle, i e. the progression through the G1 phase (the phase before DNA synthesis) into S phase (the phase of DNA synthesis).

Most oncogenic agents probably exert significance affects during the G1 phase of the cell cycle and the G1, to S transition carefully regulated by inhibitory proteins, particularly p53

Thus, cells with damaged DNA are normally blocked at this G1, checkpoint this allows time for repair of the damaged DNA, or, if that fail to switch the cell into apoptosis, so preserving the integrity of the genome.

Mutations of the **p53 gene** can therefore result in loss of regulation of the checkpoint, allowing cells with damaged DNA to undergo replication. Mutation of the p53 gene is a common and significant event in many cancers throughout the body.

Fig. 10-100 Squamous cell carcinoma. Leukoplakic lesion on the right ventrolateral surface of the tongue.

Fig. 10-102 Squamous cell carcinoma. An exophytic lesion of the posterior lateral tongue demonstrates surface nodularity and minimal surface keratin production. It is painless and indurated.

Fig. 10-101 Squamous cell carcinoma. Speckled erythroplakia of the left posterior buccal mucosa. Brush sampling had been reported to be negative for epithelial abnormality, but incisional biopsy revealed invasive squamous cell carcinoma. *(From Chi AC, Ravenel MC: AAOMP case challenge: a "speckled" lesion, J Contemp Dent Pract 6:168-172, 2005.)*

Fig. 10-103 Squamous cell carcinoma. An exophytic buccal lesion shows a roughened and irregular surface with areas of erythema admixed with small areas of white keratosis. Surface ulceration is evident.

Fig. 10-108 Squamous cell carcinoma. Ulcerated mass of the lower lip vermilion.

Fig. 10-110 Squamous cell carcinoma. Ulcerated lesion with surrounding leukoplakia on the posterior lateral and ventral tongue.

Fig. 10-109 Squamous cell carcinoma. Patient neglect can result in extensive involvement, even in a readily visible site such as the lip vermilion. This ulcerating lesion of the lower lip had been present for more than 1 year before

Fig. 10-111 Squamous cell carcinoma. Ulcerated, exophytic mass of the posterior lateral border of the tongue.

Fig. 10-112 Squamous cell carcinoma. Granular red and white lesion in the anterior floor of mouth.

Fig. 10-114 Squamous cell carcinoma. Large fungating tumor of the maxillary alveolar ridge and hard palate.

Fig. 10-113 Squamous cell carcinoma. An exophytic lesion with an irregular and pebbled surface has a linear indentation along its facial aspect resulting from pressure from the patient's lower denture. Underlying alveolar bone was extensively destroyed.

Fig. 10-115 Squamous cell carcinoma. An innocuous pebbled-surface change of the attached and marginal gingiva was interpreted as an inflammatory change until multifocal white keratoses occurred.

Histopathology

well-differentiated tumors, the neoplastic epithelium is obviously squamous in type and consists of masses of prickle cells with a limiting layer of basal cells around, the periphery. Intercellular bridges are readily recognizable

Keratin pearls are often found within the masses of inf ltrating cells, each pearl consisting of a central area of keratin surrounded by whorls of prickle cells. Nuclear and cellular pleomorphism is not prominent and there

- Moderately differentiated tumors show less keratinization and more nuclear and cellular pleomorphism and mitotic activity, **but** are still readily identified as squamous in type.
- **poorly differentiated tumors** keratinization is usually absent and the cells show prominent nuclear and cellular pleomorphism and abundant, often bizarre, mitoses.

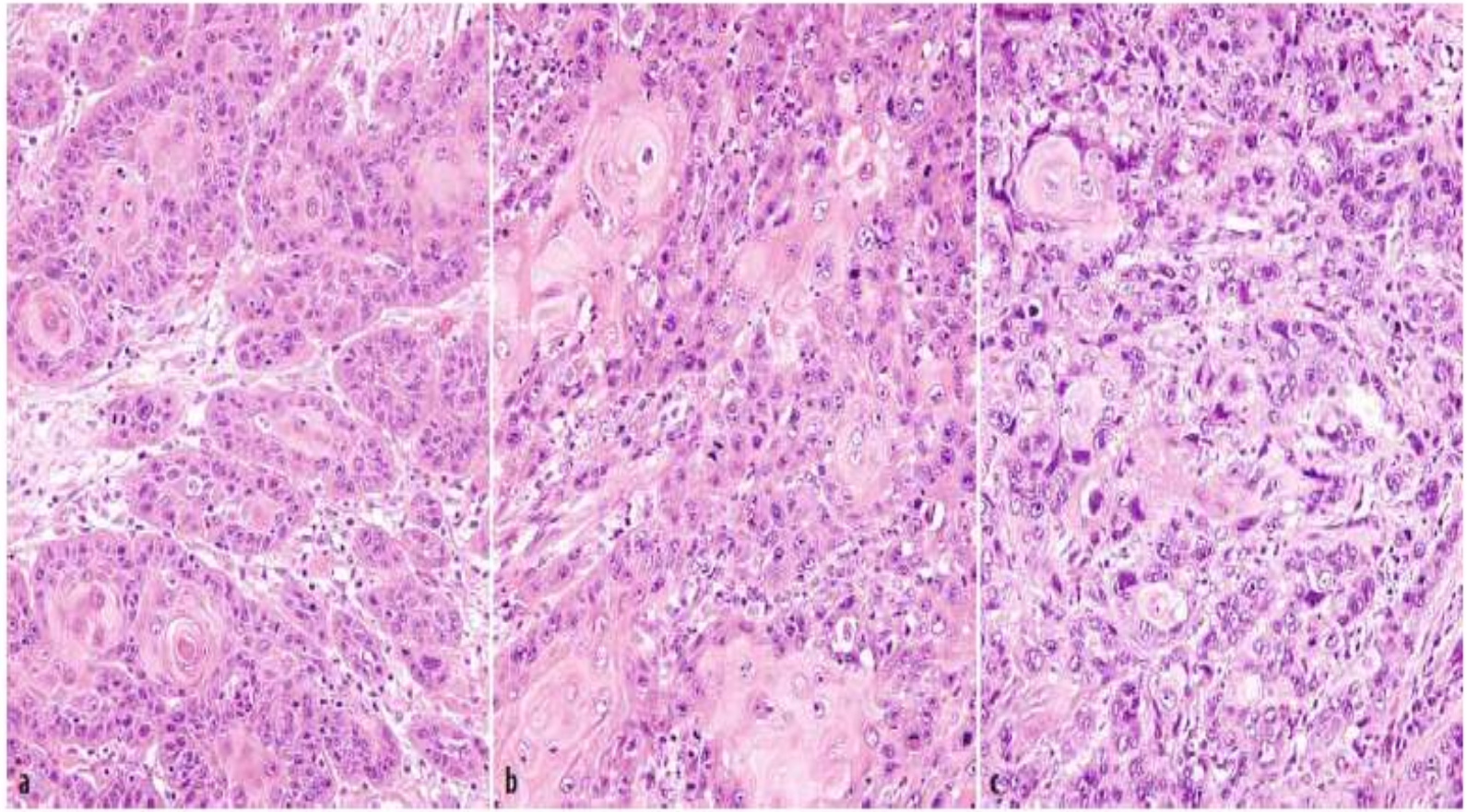

Fig. 1.13. a Well-differentiated squamous cell carcinoma. b Moderately differentiated squamous cell carcinoma. c Poorly differentiated squamous cell carcinoma

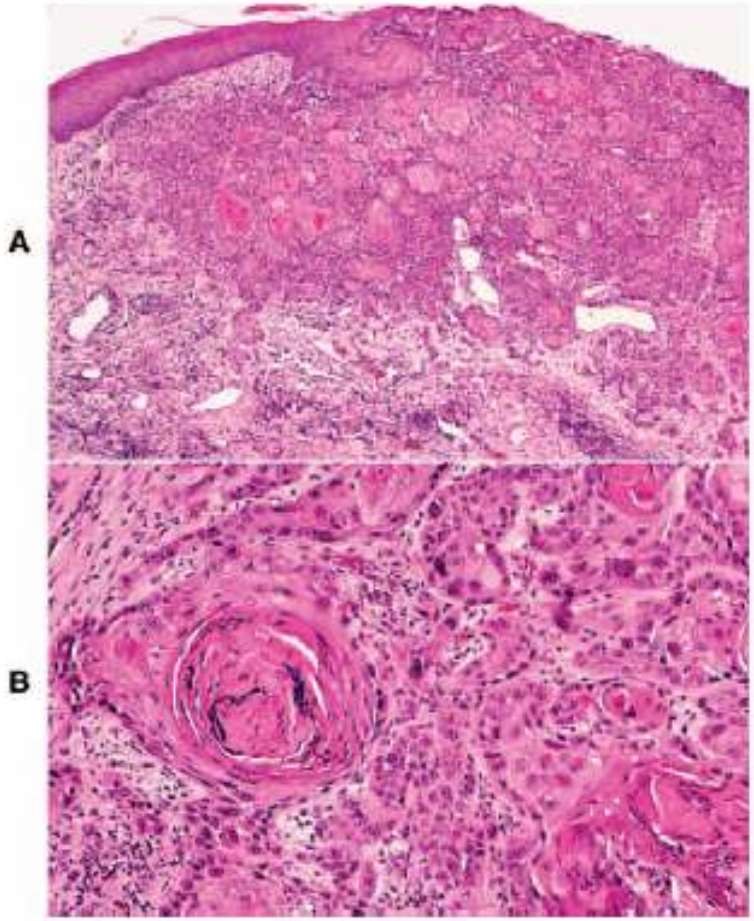

Fig. 10-119 Well-differentiated squamous cell carcinoma. A, Low-power photomicrograph showing islands of malignant squamous epithelium invading into the lamina propria. **B,** High-power view showing dysplastic epithelial cells with keratin pearl formation.

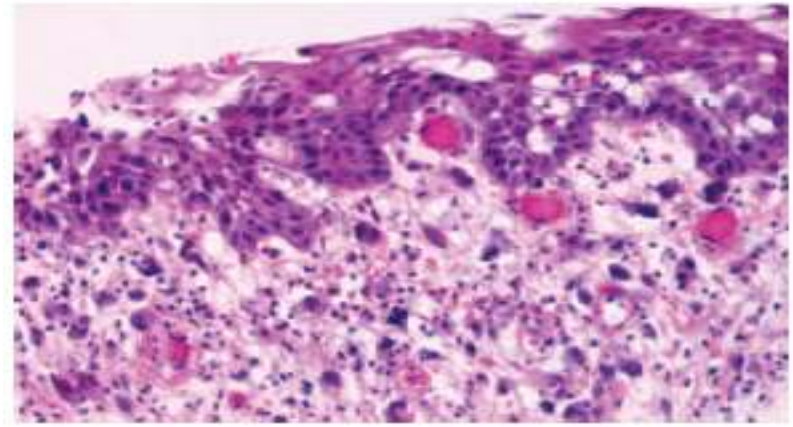

Fig. 10-120 Poorly differentiated squamous cell carcinoma. The numerous pleomorphic cells within the lamina propria represent anaplastic carcinoma.

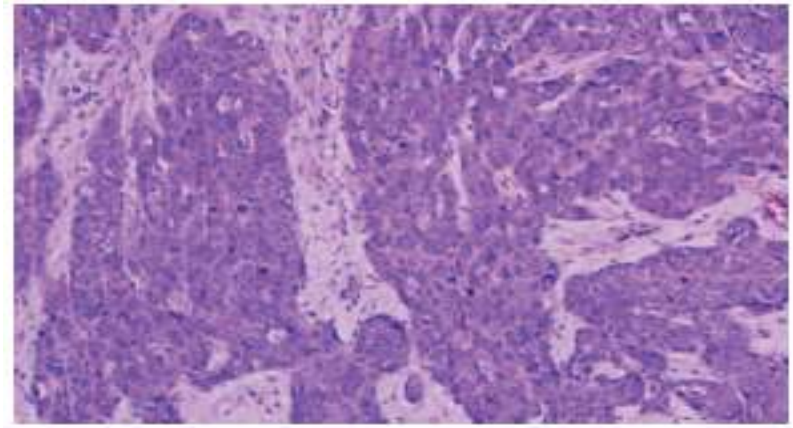

Fig. 10-121 Moderately differentiated squamous cell carcinoma. Although no keratinization is seen in this medium-power view, these malignant cells are still easily recognizable as being of squamous epithelial origin.